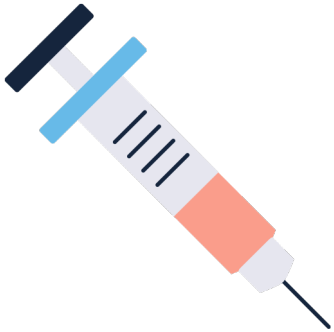




Online Materials



# Patient List

## Trauma List Scenario 1



**OrthoRevision**

1-Part Station  
10 minutes each

# Prioritisation Station



## Patient List for Candidate

#	Age	Gender	Additional Information
1	25	Male	Displaced right intra-articular fracture of distal radius (currently in A+E)
2	22	Female	Open right mid-shaft tibial fracture following RTA
3	75	Male	Left Infected TKA for washout (PMHx diabetes)
4	69	Male	Right Intra-capsular NOF# for THR
5	30	Male	Right Tibial Plateau ORIF
6	70	Female	Left Diabetic Foot Abscess




Online Materials



# Additional Information for Examiner

## Trauma List Scenario 1



**OrthoRevision**

## Additional Information for Examiner (1)

#	Age	Gender	Additional Information
1	25	Male	<b>Displaced right intra-articular fracture of distal radius (currently in A+E)</b> <ul style="list-style-type: none"><li>- Closed, NV Intact</li><li>- 12 Hours since injury. In backslab and comfortable</li><li>- PMHx: HTN</li></ul>
2	22	Female	<b>Open right mid-shaft tibial fracture following RTA</b> <ul style="list-style-type: none"><li>- 5cm open wound. N+V intact</li><li>- No contamination with aquatic / marine / sewage</li><li>- IV Abx + tetanus given</li></ul>
3	75	Male	<b>Infected TKA for washout (PMHx Diabetes)</b> <ul style="list-style-type: none"><li>- CRP 290, WCC 15</li><li>- Spiking temperatures up to 39 degrees</li><li>- Haemodynamically stable at present</li><li>- No IV Abx</li><li>- Aspirate results = gram stain +Ve</li></ul>

## Additional Information for Examiner (2)

#	Age	Gender	Additional Information
4	69	Male	<b>Intra-capsular NOF# for THR</b> <ul style="list-style-type: none"><li>- Usually fit and well. AMTS 10/10, consent form 1</li><li>- Mobilises independently. Still works at golf club.</li><li>- Optimised for theatre. Bloods normal.</li><li>- Kit Available</li></ul>
5	30	Male	<b>Tibial Plateau ORIF</b> <ul style="list-style-type: none"><li>- Closed, N+V intact, isolated injury</li><li>- Schatzker type 2 on CT scan. Joint line depression</li><li>- Requires buttress plating</li><li>- Otherwise fit and well</li></ul>
6	70	Female	<b>Diabetic Foot Abscess</b> <ul style="list-style-type: none"><li>- CRP 70, WCC 11</li><li>- Not spiking temperatures + Haemodynamically stable</li><li>- On metformin (no insulin)</li><li>- No doppler scan results.</li><li>- Awaiting USS to confirm if collection or not</li></ul>